

Peripherally Inserted Central Catheters (PICC) and the efficacy of tip placement confirmation with ECG ultrasound-guided technology and chest radiography



Elizabeth Morrell, DNP, RN, NEA-BC Scripps Mercy Hospital

4077 Fifth Avenue, San Diego, CA 92103 619-977-5058 lizmorrell@gmail.com



Background

- Acute care facilities and infusion centers in the U.S. perform 2.5 million PICC procedures annually.
- PICCs have gained popularity as a central access device due to ease of insertion, improved ultrasound technology and tip navigation.

Practice Question:

In the adult hospital setting, is advanced ECG ultrasound-guided PICC tip location technology effective as validated by the post-procedure chest radiography results?

Aims

Goal: Appraise PICC insertion placement practice utilizing ECG ultrasound-technology to enhance clinical outcomes.

Aim #1: Confirm PICC tip location by venous access nurses (VAN) via chest radiography report (CXR).

Aim #2: Examine labor costs associated with PICC insertion: in interventional radiology (IR) and VAN using ECG ultrasound-guided technology.

Method

Retrospective quality improvement study

Patient Population: adults aged 18-90 years who met indications for PICC bedside insertion.

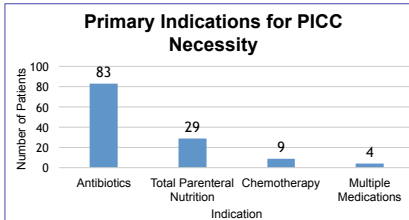
Device: Bard Inc. Sherlock 3CG® Tip Confirmation with ECG ultrasound-guided technology.

Data collection and review: electronic record review of 125 patients from July 2017-June 2016, with bedside PICCs inserted by a VAN. PICC insertion record and post-insertion CXR reviewed and results compared for accurate tip placement.

Results

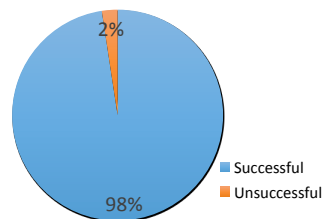
Demographics of Patients with a Bedside PICC Insertion

Male	88 (70.4%)
Female	37 (29.6%)
Age Range (years)	25-86
Mean Age (years)	62
Largest Age Group (years)	50-64



Aim #1: Confirm PICC tip location by venous access nurses (VAN) via chest radiography report (CXR).

PICC Tip Location by Venous Access Nurses compared to CXR



Analysis of PICC Insertion

•122/125 PICCs inserted into the correct position by VAN on first attempt.

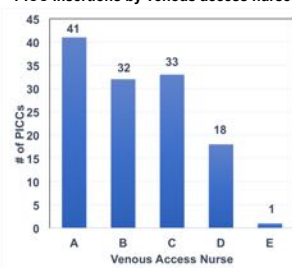
Of the 3 misplaced PICCs

- All placed too far in Right Atrium
- All females
- All dual lumen, 5FR in right arm
- 2 basilica, 1 brachial
- Height/Weight: 5'/114.6 lbs; 5'2" 141.5 lbs; 5'4"; 144 lbs
- PICC pulled back into proper position: 2cm; 3cm; 3cm

Aim #2: Analyze the average labor cost of PICCs inserted by the IR staff and the VA nurses.

	Minutes	Average Hourly Rate (US \$)	Total Cost (US \$)
At the bedside			
Venous Access RN	60	\$57.53	\$57.53
Diagnostic X-ray Tech for Portable Post CXR	15	\$39.74	\$9.94
Total Venous Access minutes and cost	75		\$67.74
In Interventional Radiology			
IR RN (incl. transport to diagnostic room X-ray – 5 minutes)	40	\$62.09	\$41.36
IR Rad Tech to assist RN for fluoroscopy	30	\$49.38	\$24.69
Diagnostic X-ray Tech for Post CXR in IR	10	\$39.74	\$6.62
Transporter (Radiology to patient room)	30	\$17.00	\$8.50
Total IR – minutes and cost	110		\$81.17

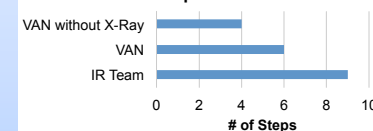
PICC insertions by venous access nurses



Implications

- The results of this study serve as a prototype to adopt this practice throughout the entire health system.
- Utilizing venous access nurses can decrease the number of steps needed to place a PICC.

Number of Steps to Insert a PICC



- Advantages for the patient include no radiation and ability to remain in their room.

Conclusion

- Venous access nurses inserting bedside PICCs is a cost effective approach in the inpatient setting.
- Cost difference between IR (\$81.17) (110 minutes) and VA nurses (\$67.47) (75 minutes) = \$13.70 difference per insertion.
- First time PICC insertions: 125 patients had a success rate of 97.6% with zero complications.
- For patients who have a p wave on ECG and in stable condition, recommend that all bedside PICC insertions with Sherlock 3CG® TCS consider elimination of the post insertion CXR.

References

References available upon request

